

## Kidney Segmentation For Finding Its Abnormalities In Abdominal CT Images

**\*M.S. Abirami and \*\*T.Sheela**

*\*Research Scholar, Department of Computer Science,  
Bharathiar University,  
Coimbatore, Tamil Nadu, India  
[abirami.srm@gmail.com](mailto:abirami.srm@gmail.com)*

*\*\* Prof. & Head, Department of Information Technology,  
Sri Sairam Engineering College,  
Chennai, Tamil Nadu, India  
[hod.it@sairam.edu.in](mailto:hod.it@sairam.edu.in)*

### ABSTRACT

This research paper addresses automatic kidney segmentation and finding its abnormalities from abdominal CT images. Identifying kidney in abdominal medical image is the fundamental step for the study of kidney pathology such as stones, tumors, cysts etc. Kidney segmentation from CT images is usually performed manually or semi-automatically because of grey levels similarities of adjacent organs, and variation in shapes and positions of organs. First, kidney position is identified based on the intensity values using Connected Component Labeling algorithm and spine as landmark. Then the kidneys are extracted using Region Growing approach. This methodology may be applied to abdominal CT images of different sizes. The method is tested on over 100 clinically acquired images and very promising results were obtained.

**Keywords:** Segmentation, CT images, Region Growing approach, Adaptive Histogram Equalization, Stone Boundary Trace approach

### I. INTRODUCTION

Automated segmentation systems are becoming important for segmenting organs and finding their abnormalities in different medical imaging modalities such as Computed Tomography (CT) images, Ultra Sound (US) images, Magnetic Resonance Imaging (MRI), and Positron Emission Tomography Images (PET) etc.

The purpose of this paper is to segment the kidneys and identifying its abnormalities from the abdominal CT images. In abdominal CT images various organs such as liver, kidney, pancreas etc. may have similar grey level intensities and also variation in shapes and positions of these adjacent organs. Therefore accurately identifying kidney positions is more difficult. There may be different abnormalities in the kidney like stones, cysts, cancer tissue etc. In the literature, various automatic and semi-automatic segmentation techniques are available.

In this paper, we propose automatic kidney segmentation from the clinical abdominal CT images for finding its abnormalities. The proposed methodology consists of five steps. First, the CT image is pre-processed using median filters. Then most of the non-kidney parts are eliminated based on intensity value by adaptive histogram equalization. The kidney position is identified using Connected Component Labeling algorithm and spine as landmark. Then seeds are identified and the kidneys are extracted using Region Growing approach. Finally, the abnormality is identified by the Boundary Trace Detection Algorithm.

The proposed algorithm differs from previous kidney segmentation algorithms in the following aspect: More than one pre-processing algorithms are applied. Our algorithm works not only for boundary detection but also refining boundary segmentation for better result. Working on 100 slices of abdominal CT images, our experiments demonstrate that the proposed algorithm improves the segmentation performance compared to other results.

The rest of the paper is divided into four sections. Section II discusses various Related Work of Image Segmentation techniques, Section III highlights on proposed methodology for abdominal CT image, Section IV briefs about Experiments and Results and Section V concludes and deals with topics for further research.

## **II. RELATED WORK**

The existing segmentation methods are Thresholding and Region based approaches, Knowledge based approaches and Deformable methods.

Several prior studies on kidney segmentation exist in the literature on different imaging modalities. The kidney segmentation is done mainly for finding abnormalities such as kidney stone, cancer, tumor etc. Kim et al. [4] combined region growing, thresholding, and histogram peak analysis to segment kidneys and kidney tumor tissue. Lin et al. [5] proposed an adaptive region growing method to identify elliptical kidneys using spine as a landmark and an anatomical model based approach for kidney segmentation on CT images. Spiegel et al. [6] proposed an active shape model for kidney segmentation on CT images. This segmentation was initialized by a seed point. Xie et al. proposed a texture and shape priors based method for kidney segmentation on ultrasound (US) images. Freiman et al. proposed a nonparametric model for kidney segmentation on CT images.

Kohlberger et al. [7] presented a level set method for organ segmentation that incorporates prior knowledge of shape and appearance for liver and kidney segmentation on CT datasets. Wu et al. [8] developed a method for 2D kidney

segmentation for US images by applying probabilistic deformable model. Linguraru et al. [9] presented a technique for multi-organ segmentation.

### **III. METHODOLOGY**

Segmenting organs in an abdominal CT image is complicated, because it may contain kidney, spine, liver, spleen, and pathologies. Also the adjacent organs may have similar intensity values as kidney. Therefore traditional kidney segmentation methods may extract undesirable boundaries from its adjacent organs as false positive errors. To perform automatic kidney segmentation, we propose a fine segmentation. First, the abdominal CT image is pre-processed using median filters. Then adaptive histogram equalization is used to eliminate the non-kidney parts based on the intensity values. Thirdly, kidney position is identified by Connected Component Labeling algorithm using spine as landmark. Also seeds are marked and fine kidney regions are extracted using Region Growing approach. Finally, the abnormality is identified from the extracted kidney regions. The proposed methodology is shown in Fig. 1.

#### **A. Pre-processing:**

For the abdominal Computed Tomography image, the threshold value is find out and pre-processed using adaptive histogram equalization and median filters.

#### **B. Kidney Position Detection:**

To obtain the kidney position, we use anatomic location of kidney. Kidney is generally located in the bottom-left and bottom-right side of abdominal CT images. We use the spine as a landmark to determine the position of kidney. Then, we eliminate most of the non-kidney parts and identify the kidney positions and its adjacent organs with the same intensity values by adaptive histogram equalization. Fig. 2 illustrates the intensity distribution of the kidneys and other parts of the abdominal CT image. From the histogram diagram, we can find and eliminate the non-kidney parts by threshold.

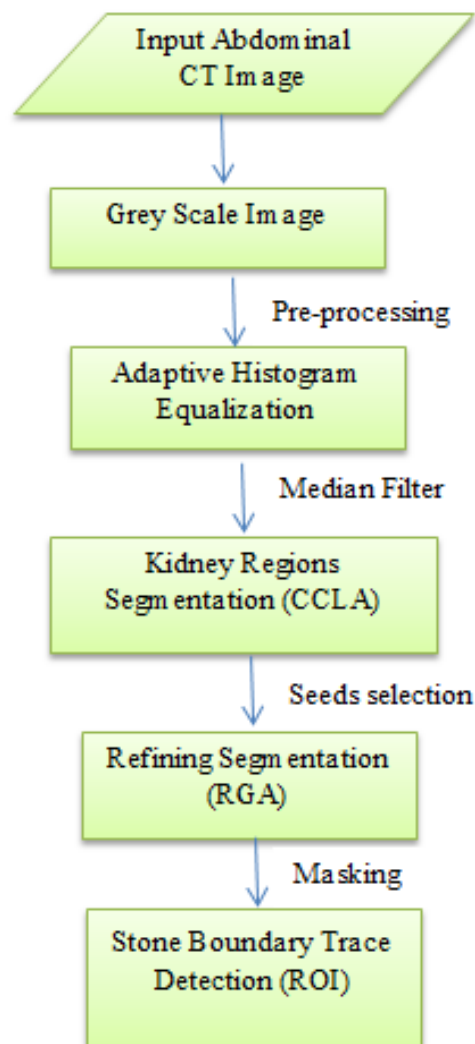


Fig. 1: Proposed Methodology

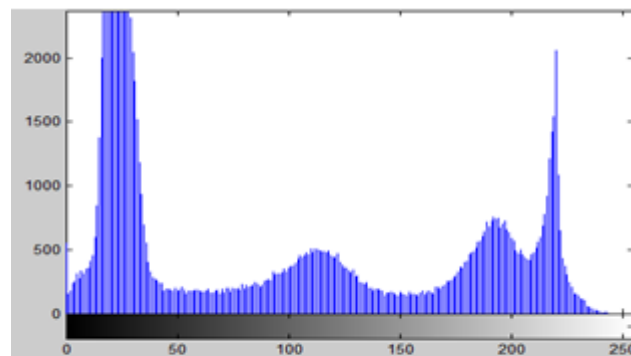


Fig. 2: Intensity Distribution of the kidney and the other organs

### C. Kidney Position Extraction:

The adaptive histogram equalization algorithm removes many non-kidney parts. But its performance is reduced with the noises such as the pixels of the other organs which have the similar intensity values with the kidney. To overcome this problem and detect the exact kidney position, we perform on the 4-connected region-labeling algorithm. Let L and R represent the left part and right part of the threshold CT image. From the following equation (1) and (2), we can obtain two regions for L and R separately, which is  $V_{Lmin}$  (1) and  $V_{Rmin}$  (2).

$$V_{Lmin} = \min \left\{ \left( \frac{\sum f_{L(i)}(j)}{C_{L(i)}} \right) / S_{L(i)} \right\} \quad (1)$$

$$V_{Rmin} = \min \left\{ \left( \frac{\sum f_{R(i)}(j)}{C_{R(i)}} \right) / S_{R(i)} \right\} \quad (2)$$

### D. Kidney Segmentation

The 4-Connected Component Labeling algorithm applied in abdominal CT images detects the kidney position. In order to obtain the fine kidney parts and to eliminate all noise parts, connected component labeling algorithm is used. Finally, Adaptive Region Growing algorithm is adopted to obtain the fine kidney region.

#### Adaptive Region Growing

The following issues need to be addressed in the region growing process: initial seed selection, the similarity criterion of growing, and the formulation of termination criterion [8]. In our proposed technique, initial seeds can be computed automatically from the pre-processed image. Also this technique follows an adaptive criterion [4].

#### Seed Generation

The advantage of automated seed selection is that it requires prior knowledge such as a location, shape and attenuation of the kidney, to select the suitable seeds for region growing. In order to obtain the initial seed point  $(x_{Li}, y_{Li})$  and  $(x_{Ri}, y_{Ri})$  for the two kidneys respectively, Let  $R_L$  and  $R_k$  denote the two kidney regions in the labeled image, and consider  $f(x_i, y_i)$  as the initial seed, where  $f(x_i, y_i) \approx V_{mean}$ . Then we compute the average intensity value as follows:

$$V_{mean} = \frac{\sum_{i=1}^m \sum_{j=1}^n f(x_i, y_j)}{m \times n}$$

### Growing Criterion

We proceed with the Region Growing algorithm once the appropriate seed is located. The homogeneous criterion is,

$$|f(x, y) - \theta_{local}| \leq t_0 \quad \forall (x, y) \in R_k$$

Where  $f(x, y)$  is a pixel satisfying the 8-connection condition around the seed.

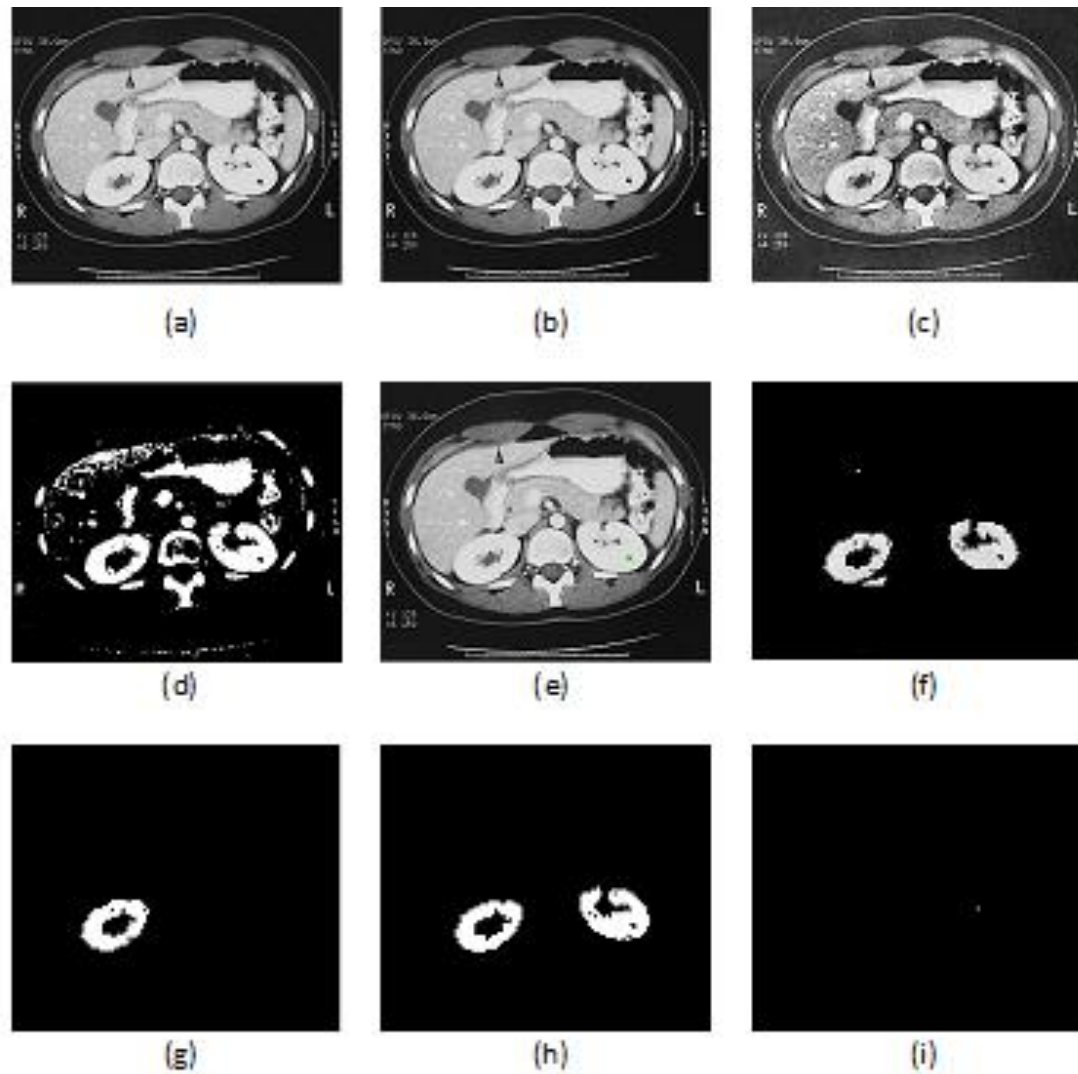
$$\theta_{local} = (R_{max} + R_{min}) / 2$$

$R_{max}$  and  $R_{min}$  denote the maximum and minimum intensity with respect to the initial seed  $(x_i, y_i)$ . The region growing process terminates when the surrounding area is not homogeneous. The threshold value is chosen based on our observation of training images.

## IV EXPERIMENTS AND RESULTS

The proposed method was tested on abdominal CT images which contain kidney, liver, spleen, spine and have adjacent that have similar intensity values as the kidney. As shown in Fig. 2, we analyze the intensity distribution of about 10 CT samples that are manually segmented kidney and adjacent organs. We obtain threshold range for the two kidneys. We use Connected Component Labeling algorithm for finding anatomic location of kidney regions. The kidneys are finally extracted based on Adaptive Region Growing, which is shown in Fig.3. Twenty randomly selected CT datasets independent of the training data were used for testing. Reference manual segmentations were created by a radiologist. We compared our segmentation with the reference segmentation to evaluate our method. The quality of the result is dependent on proper selection of the parameters such as seeds and threshold values.

In this paper, an automated kidney segmentation method abdominal CT images is developed and implemented using a prior knowledge and adaptive region growing algorithm based on connected component labeling algorithm median filtering. The proposed algorithm use adaptive threshold algorithm based on the analysis of the intensity distribution of kidney and its adjacent organs. Then, the noise is eliminated by Median filtering. An adaptive region growing algorithm with automated generation of seeds is used to obtain fine kidneys from the pre-processed image to obtain the fine kidneys. The segmentation accuracy is shown in Table I. Finally, Stone Boundary Trace algorithm is used to find the abnormality. The results are compared to manually segmented image by radiologist.



**Fig. 3: Results obtained from various algorithms (a) Input image (b) Gray Scale image (c) Adaptive Histogram Equalization (d) Median Filtering (e) Stone Identification (f) Connected Component Labeling (g) & (h) Adaptive Region Growing (i) Stone Boundary Trace**

Table I  
Segmentation of the Kidney

No.	Dataset	True Positives	True Negatives	False Positives	False Negatives	Accuracy
1	CT001	0	2621	0	0	
2	CT002	0	2621	0	0	
3	CT003	0	2621	0	0	
4	CT004	0	2621	0	0	
5	CT005	0	2621	0	0	
6	CT006	0	2621	0	0	
7	CT007	0	2621	0	0	
8	CT008	115	0	27	23	99.97%
9	CT009	233	0	17	98	99.93%
10	CT010	378	0	162	158	99.96%
11	CT011	441	0	9	101	98.27%
12	CT012	201	0	125	91	95.70%
13	CT013	185	0	109	63	96.67%
14	CT014	342	0	127	74	94.97%
15	CT015	291	0	33	110	99.55%

## V CONCLUSION AND FUTURE WORK

We incorporate relevant features for distinguishing kidney organ from other non-kidney organs in CT datasets. We determine the region of the most probable occurrence for left and right kidney in the abdominal, well-aligned CT datasets where segmentation is performed. We use intensity information to remove non-kidney regions. Also domain knowledge is introduced for landmark-based abdominal normalization. Successful segmentation is based on an estimate of the kidney location. The refining procedure improves the segmentation accuracy. All images were segmented manually by an expert to generate the ground truth.

## REFERENCES

- [1] Emmanouil Skounakis et al, "ATD: A Multiplatform for Semiautomatic 3-D Detection of Kidneys and their Pathology in Real Time," *IEEE Transactions on Human-Machine Systems*, vol. 44, no. 1, February 2014.
- [2] [4] O. Gloger, K. D. Tonnie, V. Liebscher, B. Kugelmann, R. Laqua, and H. Volzke, "Prior shape level set segmentation on multistep generated probability maps of MR datasets for fully automatic kidney parenchyma volumetry," *IEEE Trans. Med. Imag.*, vol. 31, no. 2, pp. 312–325, Feb. 2012.
- [3] [7] X. Chen, R. Summers, and J. Yao, "FEM-based 3-D tumor growth prediction for kidney tumor," *IEEE Trans. Biomed. Eng.*, vol. 58, no. 3, pp. 463–467, Mar. 2011.



- [4] D.-Y Kim and J.-W. Park, "Computer-aided detection of kidney tumor on abdominal computed tomography scans," *Acta Radiologica*, vol. 45, no. 7, pp. 791-795, 2004.
- [5] D. T. Lin, C. C. Lei, and S. W. Hung, "Computer-aided kidney segmentation on abdominal CT images," *IEEE Trans. Inform. Tech. Biomed.*, vol. 10, no. 1, pp. 59-65, Jan. 2006.
- [6] M. Spiegel, D.-A Hahn, V. Daum, J. Wasza, and J. Hornegger, "Segmentation of kidneys using a new active shape model generation technique based on non-rigid image registration," *Comput. Med. Imag. Graphics*, vol. 33, no. 1, pp. 29-39, 2009.
- [7] T. Kohlberger, M. G. Uzubas, C. Alvino, T. Kadir, D. Slosman, and G. Funka-Lea, "Organ Segmentation with Level Sets using Local Shape and Appearance Priors," G. Y. Yang, D. Rueckert, A. Noble, and C. Taylor, Eds. London, U. K.: Springer, 2009, pp. 34-42.
- [8] C. H. Wu and Y. N. Sun, "Segmentation of kidney from ultrasound B-mode images with texture-based classification," *Computer Methods Programs Biomed.*, vol. 84, no. 2, pp. 114-123, 2006.
- [9] M. G. Lingurru, J. A. Pura, A. Chowdhury, and R. Summers, "Multi-Organ Segmentation from Multi-Phase Abdominal CT via 4-D Graphs using Enhancement, shape and Location Optimization," J. Teo, Ed. New York: Springer, 2010, *Lecture Notes Computer Science*, pp. 89-96.
- [10] R. Prevost, B. Mory, J. Correias, L. D. Cohen, and R. Ardon, "Kidney detection and real-time Segmentation in 3D contrast-enhanced ultrasound images," in *Proc. 9th IEEE Int. Symp. Biomed. Imag. ISBI*, Barcelona, Spain, 2012, pp. 1559-1562.
- [11] H. Akbari and B. Fei, "Automatic 3D segmentation of the kidney in MR images using wavelet feature extraction and probability shape model," *Med. Imag., Image Process.*, vol. 8314, pp. 83143D1-83143D7, Feb. 2012.
- [12] P. R. Tamilselvi and P. Thangaraj, "Computer aided diagnosis system for stone detection and early detection of kidney stones," *J. Comput. Sci.*, vol. 7, no. 2, pp. 250-254, 2011.
- [13] S. S. Kumar, R. S. Moni, and J. Rajeesh, "Automatic segmentation of liver and tumor for CAD of liver," *J. Advances inf. technol.*, vol. 2, no. 1, pp. 63-70, Feb. 2011.
- [14] F. Khalifa, M. A. Ghar, and T. Diasty, "Dynamic contrast-enhanced MRI based early detection of acute renal transplant rejection," *IEEE Trans. Med. Imag.*, vol. 32, no. 10, Oct. 2013.
- [15] M. Mostapha *et al.*, "Dynamic MRI-based computer diagnostic systems for early detection of kidney transplant rejection: A survey," presented at the Amer. Inst. Phys. Conf. Proc., Sydney, Australia, vol. 1559, pp. 297-306, Nov. 27-29, 2013.
- [16] Jun Xie, Yifeng Jiang and Hung-tat Tsui, (2005): "Segmentation of Kidney from Ultrasound Images Based on texture and Shape Priors", *IEEE Trans. on Medical Imaging*, 24, pp. 45 - 57.

- [17] H. Rusinek, Y. Boykov, M. Kaur, S. Wong, L. Bokacheva, J. B. Sajous, A. J. Huang, S. Heller, and V. S. Lee, "Performance of an automated segmentation algorithm for 3-DMR renography," *Magn. Resonance Med.*, vol. 57, pp. 1159–1167, 2007.
- [18] K. Kumar and B. Abhishek, "Artificial neural networks for diagnosis of kidney stones disease," *I. J. Inf. Technol. Comput. Sci.*, vol. 7, pp. 2+0–25, 2012.
- [19] J. S. Jose, R. Sivakami, N. U. Maheswari, and R. Venkatesh, "An efficient diagnosis of kidney images using association rules," *Int. J. Comput. Technol. Electron. Eng.*, vol. 12, no. 2, pp. 14–20, 2012.
- [20] F. Khalifa, M. A. Ghar, and T. Diasty, "Dynamic contrast enhanced MRI based early detection of acute renal transplant rejection," *IEEE Trans. Med. Imag.*, vol. 32, no. 10, Oct. 2013.
- [21] Krishna Kant Singh, Akansha Singh, "A Study Of Image Segmentation Algorithms For Different Types Of Images," *IJCSI International Journal of Computer Science Issues*, Vol. 7, Issue 5, September, 414-417, 2010.