

Melanoma Segmentation in Dermatoscopic Images by Methods in the Space Domain

B. Luna-Benoso¹, J.C. Martínez-Perales¹, J. Córtes -Galicia¹

**Instituto Politécnico Nacional. Escuela Superior de Cómputo*

*Av. Juan de Dios Bátiz, esq. Miguel Othón de Mendizábal,
Mexico City 07738, Mexico.*

Abstract

Cancer is one of the leading causes of death worldwide. The skin cancer is a condition in which malignant cells form in the tissues of the skin, melanoma being the type of skin cancer more aggressive and more deadly. Melanoma mortality rates are associated with its high potential for metastasis in later stages, spreading to other sites in the body such as the lungs, the bones or the brain, so that their early detection and diagnosis are closely related to Survival rates. Computer-aided diagnosis (CAD) systems carry out a Pre-diagnosis of skin lesions based on information regarding clinical criteria. To perform the pre-diagnostic through a CAD system, the segmentation process is carried out first of all the image of the area affected by the injury. In this work, a methodological methodology is presented in the spatial domain that allows obtaining the segmentation of the area affected by a melanoma lesion in dermatoscopic images.

INTRODUCTION

The extraction of different entities that make up an image is a fundamental task in the image processing. This process, called segmentation, is often mandatory in all systems that handle artificial vision, and depending on the problem to be solved, have been developed different methodologies to attack each of these problems. In general terms, the segmentation of images is the process of isolating the objects that make up an image, that is, it is the partition of the image in disjunct regions, in such a way that each region is homogeneous with respect to certain properties, such as levels of gray, contrast, texture, etc. [1, 2, 3].

The segmentation of medical images serves as an important tool for the evaluation and diagnosis clinical [4, 5]. The results are useful for doctors to recognize organs and tissues correctly, thus increasing the efficiency of the diagnosis and reducing the workload in the analysis of images medical. However, the segmentation in medical images is particularly difficult due to the restrictions imposed by the acquisition of images, pathologies and biological variations [6, 7, 8].

Skin cancer is a disease caused by the abnormal development of cancer cells in any of the layers of the skin. There are two types of skin cancer, the non-melanoma type and the type melanoma [9, 10, 11]. The non-melanoma type occurs in the outermost layer of the skin presenting itself as a nodule or a

skin lesion that is not painful, ulcerated and crusted, which does not heal with the passage of time, its growth is slow and rarely extends to other organs of the body [11, 12]. On the other hand, melanoma is the most aggressive type of cancer, if it is not diagnosed in time it is likely to invade nearby tissues and spread to other parts of the body [13], which is why melanoma is considered as the deadliest form of skin cancer, and early detection is crucial for patient survival. A problem that is usually found by health specialists is that the detection is mainly done in a visual way, and this is a challenge, since melanoma is an injury that It usually looks like benign skin lesions. Every year there is a significant increase in annual fees of all forms of skin cancer, something worrisome, considering that the melanoma type increases rapidly in the world among the other forms of cancer, particularly affecting the population young [14, 15]. The diagnosis of melanoma is an unsatisfactory task due to the clinical interpretation and the lack of reproducibility.

For the diagnosis of skin cancer, the first step is to obtain a medical history of the patient, afterwards, a physical examination is performed. If the doctor suspects the presence of a melanoma, he will use a technique called dermatoscopy to observe the skin more clearly. The dermatoscopy consists of in using a light source on the affected area and a type of lens to enlarge the affected area, obtaining in this way an image of the affected area which is called dermatoscopic image.

The doctor will use the dermatoscopic image to give a possible diagnosis, in case him still have the uncertainty if it were a melanoma, then a biopsy will be used. The analysis of the image dermatoscopy is of paramount importance to make a decision in case of applying an invasive method such as what is the biopsy [16, 17, 18].

Computer-aided systems (CAD) applied to dermatoscopic images of patients who suffering from melanoma has helped in the work of performing pre-diagnoses in a rapid manner [19, 20, 21]. For this, one of the first tasks of CAD systems is the segmentation of the area affected by melanoma, to later perform the extraction of characteristics and their classification [21]. This work focuses in the segmentation of melanoma in dermatoscopic images using methods in the spatial domain, for this, the image bank PH2 database was used [22]. This image bank contains 200 images dermatoscopy of melanocytic lesions, including common nevi, atypical nevi and melanomas

BASIC CONCEPTS

Digital image

A digital image is a two-dimensional function $f(x, y)$ of the light intensity (brightness) at a point in the space, being (x, y) the coordinates of said point considering the origin in the

upper left part of the image [23]. Since a digital image is a function $f(x, y)$ discretized both in the coordinates spatial as in brightness, it is often represented as a two-dimensional matrix $F_{ij} = (f_{ij}) H \times W$, where H and W represent the size of the image, (referring to H and W at height and width of the image respectively) with $f_{ij} = f(x_i, x_j)$ (Figure 1).




Figure 1: Digital image.

Histogram of the Image

The histogram of a digital image with gray levels in the range [0, 255] is a discrete Histo [k] function that represents the number of colors for each level of gray ($k = 0, \dots, 255$). The graphic representation of this function for all the values of k provides a global description of the appearance of the image [23]. Although the histogram does not indicate something specific about the content of the image, it does provide us with very useful information about the possibility of highlighting characteristics of interest of the same.

PROPOSED MODEL

In this section we present the proposed methodology that allows the detection of injuries affected by melanoma on the skin from dermatoscopic images. This is done using methods in the domain space. Consider a dermatoscopic image like the one shown in figure 2.

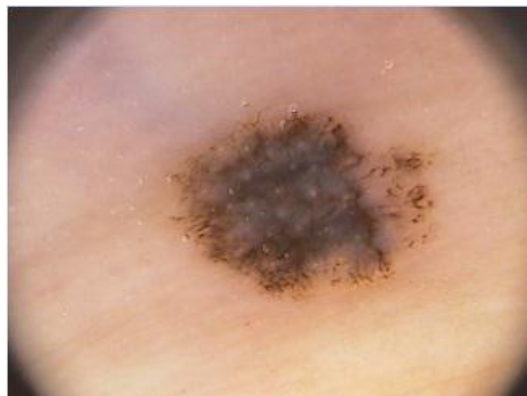

Figure 2: Dermatoscopic image of a lesion with melanoma.

Step 1. Given an image like the one shown in figure 2, the medium filter was first applied with the aim of reducing the amount of intensity variations between neighboring pixels.

Step 2. The Otsu method was used to binarize the image that was previously applied to filter of median. The Otsu method uses statistical techniques that allow solving the problem of the binarization. Use the variance as a measure of dispersion to calculate the threshold so that the dispersion within each

class is as small as possible, but at the same time the dispersion is as high possible between different classes.

Figure 3 shows the image of Figure 2, to which the medium gray scale filter was applied with the RGB model, to later calculate the value of the binarization threshold with the Otsu and fi method. the binarized image is displayed.

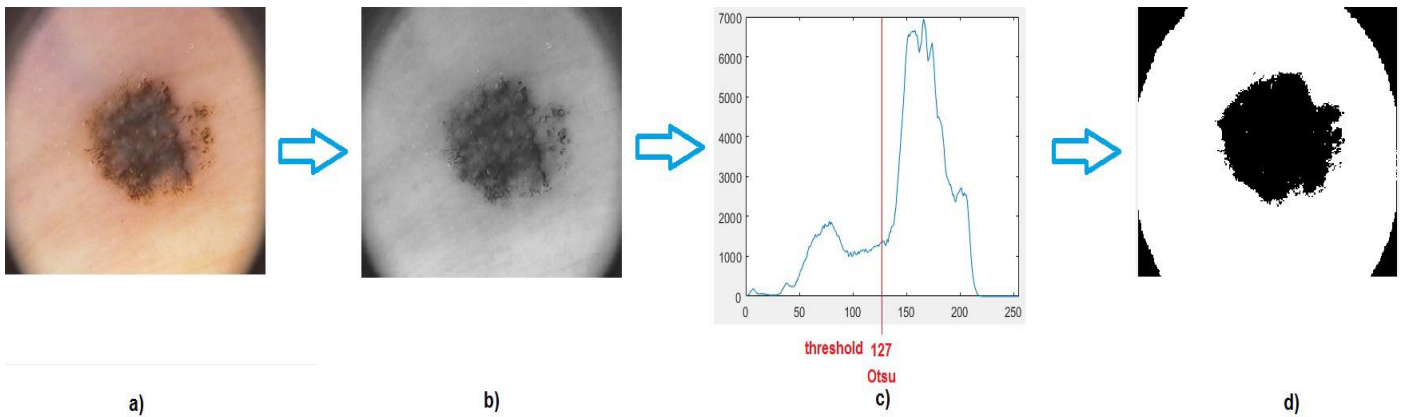


Figure 3: a) dermatoscopic image, b) median filter, c) threshold by Otsu method, d) binary image by Otsu method.

Step 3: The corners of the dermatoscopic images were removed, for this, the following way was done. We considered the circumference that passes through the periphery of the corners of the dermatoscopic image, for this, the center of the circumference was considered as the center of the image, that is, the center has as coordinates $(C_x, C_y) = (H / 2, W / 2)$. Once the center was located, the straight lines joining the diagonals of the image and passing through the center were considered, on these lines the distance of the point was calculated (C_x, C_y) to the points on the lines that intersect the binary image by the internal part of the image. In this way, 4 distances were obtained from the point (C_x, C_y) to each of the corners of the image binary by the internal part, these points correspond to points on the periphery of the circumference with center (C_x, C_y) and radius the point obtained. Since we obtained 4 distances corresponding to each of the points of the corners, we considered the point that was closer to the center, let's call this point (a_x, a_y) and let r be the distance between (a_x, a_y) and (C_x, C_y) , that is: $r = \sqrt{(C_x - a_x)^2 + (C_y - a_y)^2}$. Subsequently, the

points that are outside the circumference with center were eliminated from the image (C_x, C_y) and *radius* (a_x, a_y) , this is:

$$f(x,y) = \begin{cases} 255 & \text{si } (C_x - x)^2 + (C_y - y)^2 \geq r^2 \\ 0 & \text{en caso contrario} \end{cases}$$

Figure 4 shows the process and the result of the elimination of the corners of the binary image. The diagonals are shown that cross over the center, the radius and then the elimination of all those pixels that are outside the circumference with center (C_x, C_y) and radius (a_x, a_y) .

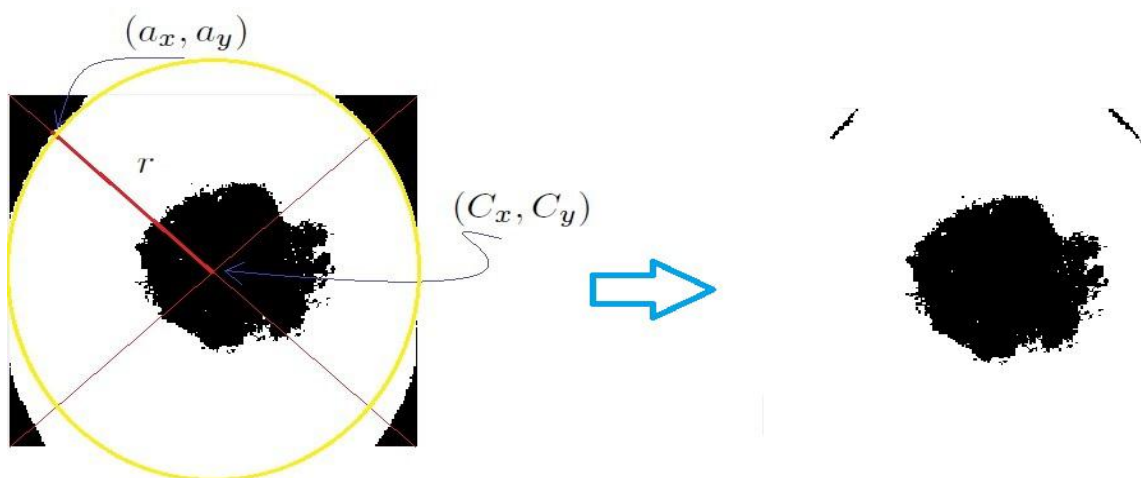


Figure 4: Process of elimination of the corners of the image resulting from applying the Otsu method.

Step 4: Morphological erosion was applied three times and then a morphological dilatation three times, both using Von Neumann's neighborhood. Figure 5 shows the result of applying step 4 to the image from Figure 4.




Figure 5: a) neighborhood of Von Neumann, b) result of applying three times a morphological erosion and c) result of applying three times a morphological dilatation.

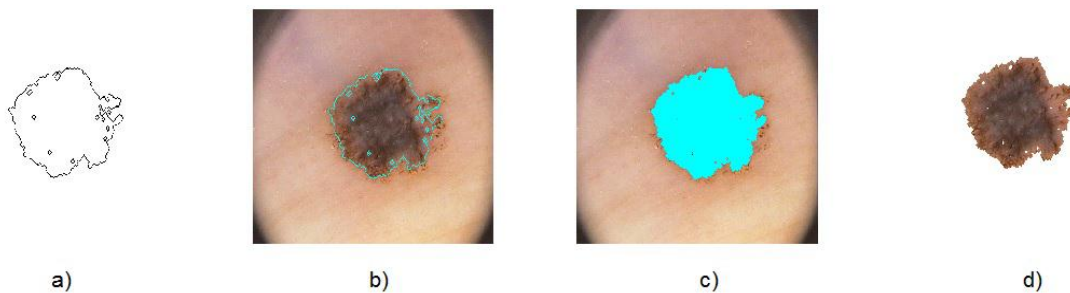


Figure 6: a) contour of the lesion, b) outline of the lesion on the dermatoscopic image, c) area of the lesion and d) segmented lesion corresponding to melanoma.

Figure 6-a) shows the contour of the binary image of Figure 5, 6-b) shows the contour on the original dermatoscopic image (corresponding to Figure 2), 6-c) shows the area enclosed by the contour on the image of Figure 2, this corresponds to the lesion, and finally Figure 6-d) shows the segmentation of the area of the injury.

Figure 7 shows the segmented area of the lesion that presents melanoma, both its representation and image and its representation as a function in the three-dimensional coordinate space.

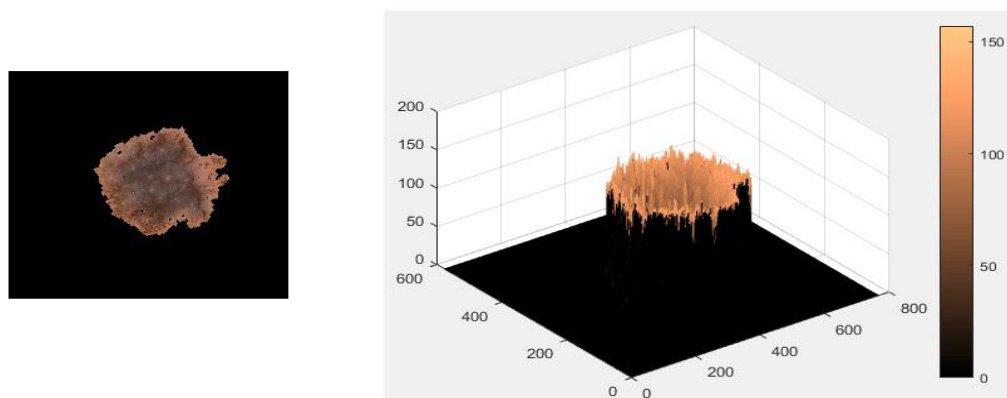


Figure 7: Segmentation of the area that presents melanoma in a dermatoscopic image.

EXPERIMENTS AND RESULTS

This work makes use of images obtained from the ph2 data bank database [22]. The data bank consists of a total of 200 dermatoscopic images of melanocyte lesions, among which they include common nevi, apical nevi and melanomas. The dermatoscopic images were obtained from Dermatological service of the Pedro Hispano hospital in Matosinhos, Portugal. The same conditions were considered through the Tuebinger

Mole Analyzer system using a 20x magnification. The images were stored in 8-bit RGB format with a resolution of 768x560 pixels. Given the images of the data bank ph2 database, we proceeded to apply the proposed methodology, for this, first we considered the image in gray scale through its RGB channels to later apply the median filter and each of the proposed steps in section 2. Figure 8 shows the process of applying each of the steps of the methodology to different images of the image bank ph2 database.

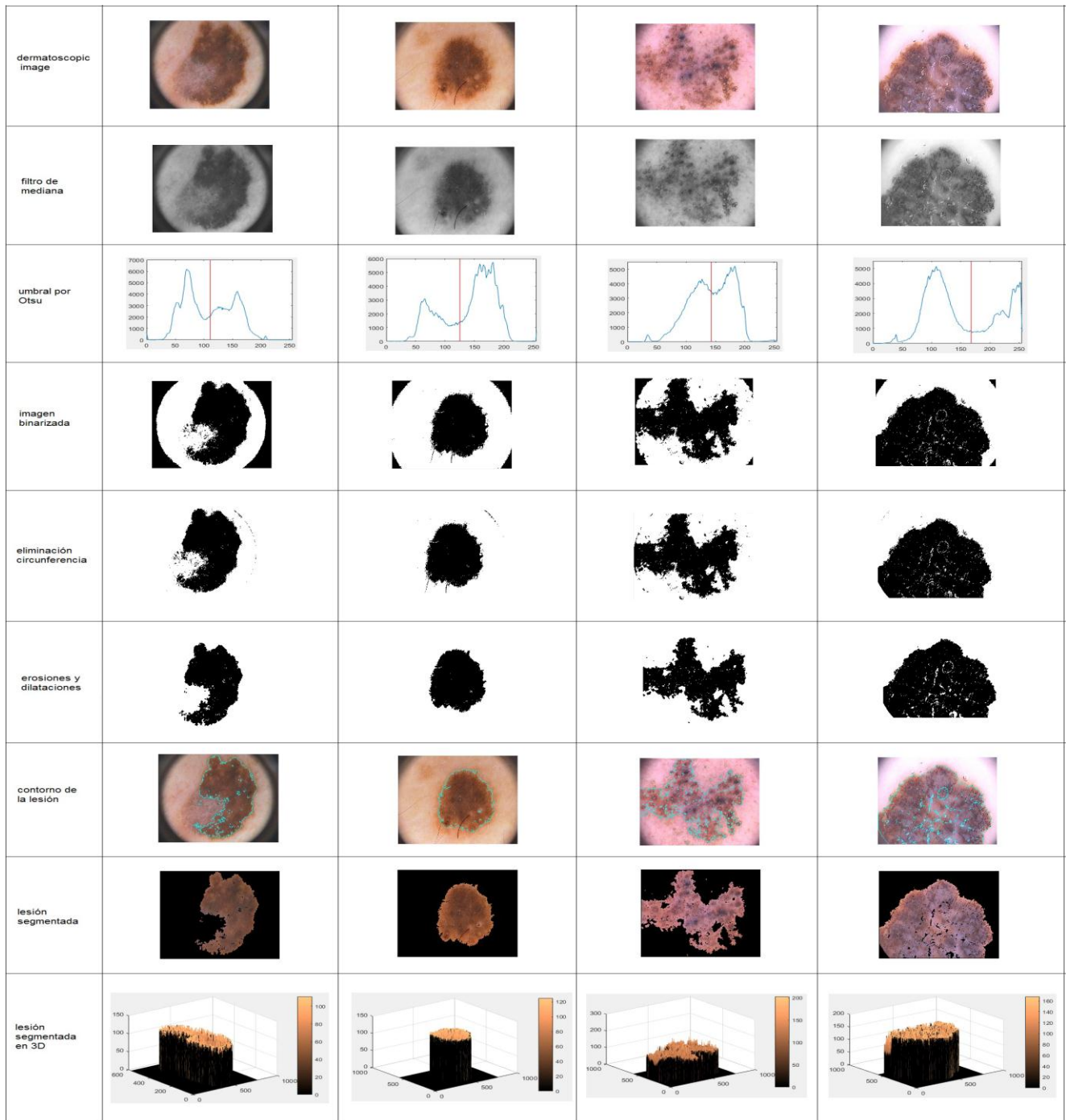


Figure 8: Segmentation of the area that presents melanoma in a dermatoscopic image.

CONCLUSION

In this work we present a methodology that allows the segmentation of skin lesions in dermatoscopic images. The methodology is based on methods in the spatial domain. To do this, the images obtained from PH2 database were converted to gray scale, to which the median filter was applied to soften the image, later the Otsu method was applied to find the threshold optimal for the binarization of the image under the criterion of maximum variance between the background and the object. Once binarized the image, proceeded to find the equation of the circumference enclosing the area of the lesion, discarding all those pixels that are on the outside of the circumference. Then erosions and morphological dilatations were applied to obtain the segmented zone.

ACKNOWLEDGEMENTS

The authors would like to thank the Instituto Politécnico Nacional (Secretaría Académica, COFAA, EDD, SIP and ESCOM) for their economical support to develop this work.

REFERENCES

- [1] Chafik Djalal Kermad, Kacem Chehdi. (2002). Automatic image segmentation system through iterative edgeregion co-operation. *Image and Vision Computing*, Volume 20, Issue 8, Pages 541-555.
- [2] Hai Gao, Weisi Lin, Ping Xue, Wan-Chi Siu. (2006). Marker-based image segmentation relying on disjoint set union. *Signal Processing: Image Communication*, Volume 21, Issue 2, Pages 100-112.
- [3] Terol-Villalobos I., R., Mendiola-Santibáñez J., D., Canchola-Magdaleno S., L. (2006). Image segmentation and filtering based on transformations with reconstruction criteria. *Original Research Article Journal of Visual Communication and Image Representation*, Volume 17, Issue 1, Pages 107-130.
- [4] JérômeSchmid, Jinman Kim, Nadia Magnenat-Thalmann. (2011). Robust statistical shape models for MRI bone segmentation in presence of small field of view. *Original Research Article Medical Image Analysis*, Volume 15, Issue 1, Pages 155-168.
- [5] R. Chrstek, M. Wolf, K. Donath, H. Niemann, D. Paulus, T. Hothorn, B. Lausen, R. Lmmer, C.Y. Mardin, G. Michelson .(2005). Automated segmentation of the optic nerve head for diagnosis of glaucoma. *Original Research Article Medical Image Analysis*, Volume 9, Issue 4, Pages 297-314.
- [6] Chuan-Yu Chang, Pau-Choo Chung, (2001). Medical image segmentation using a contextualconstraint-based Hop_eld neural cube. *Image and Vision Computing*, Volume 19, Issues 9-10, Pages 669-678.
- [7] Olabarriaga S., D., Smeulders A., W., M. (2001). Interaction in the segmentation of medical images: A survey. *Medical Image Analysis*, Volume 5, Issue 2, Pages 127-142.
- [8] Shuo Li, Thomas Fevens, Adam Krzyzak, Song Li. (2006). Automatic clinical image segmentation using pathological modeling, PCA and SVM. *Engineering Applications of Artificial Intelligence*, Volume 19, Issue 4, Pages 403-410.
- [9] Zhen M, Joao M. R. S. (2017). Effective features to classify skin lesions in dermatoscopic images. *Expert Systems with Applications*. Vol 84, Pages 92-101.
- [10] Chatterjee S., Dey D., Munshi S. (2018). Optimal selection of features using wavelet fractal descriptors and automatic correlation bias reduction for classifying skin lesion. *Biomedical signal processing and control*. Vol 40, pages. 252-262.
- [11] Emma Craythorne, Firas Al-Niami. Skin cancer. *Review article Medicine*, Volume 45, Issue 7, July 2017, Pages 431-434.
- [12] Saverio Caini, Mathieu Boniol, Giulio Tosti, Serena Magi, Sara Gandini. Vitamin D and melanoma and non-melanoma skin cancer risk and prognosis: A comprehensive review and meta-analysis. *European Journal of Cancer*, Volume 50, Issue 15, October 2014, Pages 2649-2658.
- [13] Hongming Xu, Richard Berendt, Naresh Jha, Mrinal Mandal. Automatic measurement of melanoma depth of invasion in skin histopathological images. *Micron*, Volume 97, June 2017, Pages 56-67.
- [14] Nidhal K. El abjadi and Zahraa Faisal. Detection and Analysis of skin cancer from skin lesions. *International Journal of Applied Engineering Research*. Vol. 12, Issue. 19. 2017. pages: 9046-9052.
- [15] Andreas Nylund. To be, or not to be Melanoma. Convolutional neural networks in skin lesion classification. Degree Project in Medical Engineering. Stockholm, Sweden, 2016. KTH Royal Institute of Technology School of Technology and Health.
- [16] A. Howard, S. Peach. Cutaneous melanoma. *Surgery (Oxford)*, Volume 24, Issue 1, 1 January 2006, Pages 21-26.
- [17] Babar K. Rao, Christine S. Ahn. Dermatoscopy for Melanoma and Pigmented Lesions. *Dermatologic Clinics*, Volume 30, Issue 3, July 2012, Pages 413-434.
- [18] Zrinjka Pastar, Jasna Lipozencic. Significance of dermatoscopy in genital dermatoses. *Clinics in Dermatology*, Volume 32, Issue 2, MarchApril 2014, Pages 315-318.
- [19] Catarina Barata, M. Emre Celebi, Jorge S. Marques. Development of a clinically oriented system for

melanoma diagnosis. Pattern Recognition, Volume 69, September 2017, Pages 270-285

- [20] Fatemeh Torkashvand, Mehdi Fartash. Automatic Segmentation of Skin Lesion Using Markov Random Field. Canadian Journal of Basic and Applied Sciences. Vol 3, issue 3, March 2015, pages 93-107.
- [21] Fekrache Dalila, Ameer Zohra, Kasmi Reda, Cheri_Hocine. Segmentation and classification of melanoma and benign skin lesions. Optik - International Journal for Light and Electron Optics, Volume 140, July 2017, Pages 749-761.
- [22] Teresa sa Mendonca, Pedro M. Ferreira, Jorge Marques, Andre R. S. Marcal, Jorge Rozeira. PH - A dermoscopic image database for research and benchmarking, 35th International Conference of the IEEE Engineering in Medicine and Biology Society, July 3-7, 2013, Osaka, Japan.
- [23] Gonzalez R, Woods J. (2008). Digital image processing, 3rd edn. Prentice Hall, New Jersey.